

**ARTÍCULO ORIGINAL****CAN AMNIOTIC FLUID BE AN ALTERNATIVE ORGAN PRESERVATION SOLUTION FOR COLD RENAL STORAGE?***¿PUEDE EL LÍQUIDO AMNIÓTICO SER UNA SOLUCIÓN ALTERNATIVA DE CONSERVACIÓN DE ÓRGANOS PARA EL ALMACENAMIENTO RENAL EN FRÍO?*Başak Büyük<sup>1</sup>, Tuba Demirci<sup>2</sup>, Yasemen Adalı<sup>3</sup>, Hüseyin Avni Eroğlu<sup>4</sup>

1) Department of Histology and Embryology, Faculty of Medicine, İzmir Democracy University, İzmir, Turkey

2) Department of Histology and Embryology, Faculty of Medicine, Atatürk University, Erzurum, Turkey

3) Department of Pathology, Faculty of Medicine, Çanakkale Onsekiz Mart University, Çanakkale, Turkey

4) Department of Physiology, Faculty of Medicine, Çanakkale Onsekiz Mart University, Çanakkale, Turkey

Rev Nefrol Dial Traspl. 2019; 40 (01): 14-24

**ABSTRACT**

**Introduction:** Kidney-transplantation is a life-saving treatment option for patients with chronic renal failure. Preserving the viability of the organ from the removal of the organ until transplantation into the recipient is one of the most essential factors affecting postransplant success. Kidney tissue is exposed to ischemia following removal of the organ from the donor, initiating some cellular events. Amniotic fluid (AF) was previously reported as a preservation solution for the liver, but not for the kidney yet. The aim of this study is to investigate the effectiveness of AF as a preserving solution for rat kidneys compared with the University of Wisconsin (UW) and Histidine-Tryptophan-Ketoglutarate (HTK), which are reported to be the most commonly used and preferred preserving solutions. **Methods:** Forty male Wistar albino rats were used in this study in four experimental groups. Group 1: Ringer Lactate (RL, Control) group, Group 2: HTK group, Group 3: UW group, and Group 4: AF group. A midline incision was performed, and the renal artery was isolated under ketamine and xylazine anesthesia. Solutions relevant for groups (cooled to + 4°C) were used for kidney perfusion. Nephrectomy was applied, and the removed kidneys were placed into + 4°C

standard organ storage solution and stored at + 4° C for 12 hours. After 12 hours of storage, samples from the kidney tissues were fixed in 10% neutral buffered formalin. Histopathological, immunohistochemistry evaluation and apoptosis detection via TUNEL method were performed.

**Results:** The results of the AF group were close to those of the UW and HTK groups. Tubular necrosis and vacuolization were high in the RL solution group when compared to the other experimental groups. Immunohistochemistry staining for all three markers (TNF-alpha, IL-18, and iNOS) was decreased in the amniotic fluid group, similar to the UW and HTK groups. Also, the number of apoptotic cells was decreased in the AF group compared to control. **Conclusions:** UW, HTK, and AF had similar and higher protective effects compared to the RL solution. Thus, AF may be used as an inexpensive and readily available alternative natural tissue preservation solution.

**KEYWORDS:** amniotic fluid; cold ischemia; Wistar rats; organ preservation

**RESUMEN**

**Introducción:** El trasplante de riñón es una

opción de tratamiento que puede salvar la vida de pacientes con insuficiencia renal crónica. Preservar la viabilidad del órgano desde su extracción hasta el momento del trasplante en el receptor es uno de los factores principales que influyen en el éxito postrasplante. El tejido renal está expuesto a la isquemia después de la extracción del órgano del donante, lo cual da inicio a algunos eventos celulares. Existen estudios que indican que el líquido amniótico (LA) funciona como una solución de conservación para el hígado, pero aún se desconoce si sucede lo mismo con el riñón. El objetivo de este estudio es investigar la efectividad del LA como solución conservadora para los riñones de ratas, en comparación con la solución de Wisconsin (UW) y la solución de histidina-triptófano-cetoglutarato (HTK), que son los conservantes más utilizados y preferidos.

**Material y métodos:** Se emplearon cuarenta ratas albinas macho de la cepa Wistar en este estudio, en cuatro grupos experimentales. Grupo 1: grupo solución de lactato sódico compuesta (LSC, Control); Grupo 2: grupo HTK; Grupo 3: grupo UW y Grupo 4: grupo LA. Habiendo aplicado anestesia con ketamina y xilazina, se realizó una incisión en la línea media y se aisló la arteria renal. Se utilizaron soluciones relevantes para grupos (enfriadas a + 4° C) para perfusión renal. Se realizó una nefrectomía, y los riñones extraídos fueron colocados en una solución estándar de almacenamiento de órganos a + 4° C y se conservaron así durante 12 horas. Después de dicho periodo de almacenamiento, las muestras de los tejidos renales se fijaron en formalina tamponada neutra al 10%. Se llevaron a cabo una evaluación histopatológica e inmunohistoquímica y una detección de apoptosis mediante el método TUNEL.

**Resultados:** Los resultados del grupo LA fueron cercanos a los de los grupos UW y HTK. La necrosis tubular y la vacuolización fueron más altas en el grupo de la solución LSC que en los otros grupos experimentales. La tinción inmunohistoquímica para los tres marcadores (TNF-alfa, IL-18 e iNOS) disminuyó en el grupo de líquido amniótico, similar a los grupos UW y HTK. Además, el número de células apoptóticas

menguó en el grupo LA, en comparación con el de control. **Conclusiones:** UW, HTK y LA tuvieron efectos protectores similares y superiores en comparación con la solución LSC. Por lo tanto, el LA puede usarse como una solución alternativa de bajo costo para la preservación de tejidos naturales.

**PALABRAS CLAVE:** líquido amniótico; isquemia fría; ratas Wistar; preservación de órganos

## INTRODUCTION

Kidney transplantation remains the most suitable and effective treatment option for patients suffering end-stage renal failure. However, some unavoidable cellular processes, such as cold/warm ischemia, can occur during transplantation.<sup>(1)</sup> The cold ischemia process is destructive for early graft function. This process may also result in primary non-function (PNF) or delayed graft function (DGF). Additionally, one of the most significant problems in kidney transplantation is the high rate of DGF after the surgical process, affecting approximately 30% of renal transplants worldwide.<sup>(2)</sup>

The main goal of kidney preservation during the transplantation process is to maintain cellular integrity and organ functions during the time between organ harvesting and transplantation. At this point, a specific and useful preservation solution is necessary for cold storage to prevent some negative processes such as cold-ischemic injury, oxidative stress-induced injury, and cell swelling<sup>(3)</sup>. Extension of ischemic tolerance and handling of the process with minimal cell damage are improvements in kidney preservation.<sup>(4)</sup>

The most commonly used organ preservation solutions are the University of Wisconsin (UW) solution, Histidine-Tryptophan-Ketoglutarate (HTK) solution, Celsior (CS), Collins, and Euro-Collins solutions.<sup>(5)</sup>

Amniotic fluid (AF) is a colorless solution that contains water and various chemical agents such as electrolytes, peptides, lipids, carbohydrates,

proteins, and hormones. Additionally, it has antimicrobial property, regeneration capacity, and bone-tendon-healing effects. Recently, AF was used for the preservation of biological tissues, and it was reported as a good alternative to other storage media regarding its nutritional, antimicrobial, and growth promoting components.<sup>(6-8)</sup>

AF was used as preservation solution for cold storage of the liver previously. It was demonstrated that AF preserved liver tissues as effectively as standard solutions, and it decreased apoptotic cell counts as well.<sup>(8)</sup>

To the best of our knowledge, amniotic fluid has not previously been reported as a preservation solution for the kidney. This study aimed to investigate the effect of AF as a preservation solution for rat kidneys compared with UW and HTK, the most preferred and used preservation solutions.

## MATERIAL AND METHODS

### Materials and experimental design

This study was supported by the Scientific and Technological Research Council of Turkey (Tübitak) (Project number: 216S238).

Forty male Wistar Albino rats were used in this study. The rats used in experiments were purchased from Çanakkale Onsekiz Mart University. The study was approved by Çanakkale Onsekiz Mart University Ethics Committee (ethical approval date: feb. 29, 2016 and IRB number: 2016/02-03). Animal procedures were performed according to the *Guide for the Care and Use of Laboratory Animals* principles.<sup>(9)</sup> The animals were housed in standard rat cages, maintained in our laboratory under controlled environmental conditions (an air-conditioned room at room temperature  $25 \pm 2^\circ \text{C}$ , at standard humidity (30% to 40%), and with a 12 h light/dark cycle).

### Supply and preparation of the amniotic fluid

Amniotic fluid was collected from patients who were referred to the Department of Obstetrics at Çanakkale Onsekiz Mart University, who had no history of smoking, alcohol, or drug use. AF of 5-10 ml was taken during cesarean section

surgery before the amniotic pouch was dissected. Immediately after collection, AF was placed into tubes and centrifuged at 3000g for 10 min at  $4^\circ \text{C}$  to discard precipitates. Then, AFs was stored at  $-80^\circ \text{C}$ . On the experiment day, the frozen AF was warmed up to  $4^\circ \text{C}$ , centrifuged at 4000 rpm for 10 min twice, and the pellet was decanted. The final AF was filtered through a 0.22-micron filter (Merck Millipore, Cat no: GVWP06225) and used immediately.

### Experimental groups and surgical procedure

Forty 10-week old male Wistar Albino rats were randomly assigned to the following groups:

- 1) Ringer Lactate (RL) solution group (Group 1, n=10).
- 2) Histidine-Tryptophan-Ketoglutarate (HTK) solution group (Group 2, n=10).
- 3) University of Wisconsin (UW) solution group (Group 3, n=10).
- 4) Amniotic fluid (AF) solution group (Group 4, n=10).

An abdominal midline incision was performed on the rats under a mixture of 50 mg/kg Ketamine hydrochloride (Ketalar®, Pfizer, Turkey) and 10 mg/kg Xylazine (Rompun®, Bayer, Canada) anesthesia. The renal artery was entered with a polyethylene catheter, and relevant solutions for each experimental group (cooled to  $+4^\circ \text{C}$ ) were injected, and the kidneys were perfused. The renal vein was cut, and kidney perfusion continued until clear fluid came from the vena renalis. Then nephrectomy was performed. After nephrectomy, all rats were sacrificed with high dose anesthetic administration. The removed kidneys were placed in Falcon tubes each containing  $+4^\circ \text{C}$  RL, HTK, UW, or AF solutions (15 ml), and stored at  $+4^\circ \text{C}$  for 12 hours. Tissue samples were taken from the perfused kidneys for histopathological examination at 6<sup>th</sup> and 12<sup>th</sup> hours. After 12 hours of storage, samples from kidney tissues were fixed in 10% neutral buffered formalin.

### Histopathological examinations

After the kidneys were removed, each sample was consecutively numbered and quickly placed

in 10% neutral buffered formalin for histological examinations. Then, the kidneys were dehydrated in graded alcohol series (70%, 80%, 96% and 100%, respectively), cleared in xylene (10 min, 3 times) and embedded in paraffin wax. Then 5 µm serial sections were cut using a microtome (Leica RM 2125 RTS). The sections were stained with hematoxylin-eosin (H-E) and assessed under a light microscope (Zeiss AxioScope A1) with a camera attachment. Tubular necrosis, vacuolization and dilatation of Bowman's space parameters were evaluated in light microscopic examinations, which employed a scale ranging from 0 to 3 as follows:

- 0=No changes found
- 1=Mild change
- 2=Moderate change
- 3=Severe change

### Immunohistochemical evaluation

In addition to histopathology analyses, TNF-alpha, IL-18, and iNOS immune markers were used to investigate the ischemic damage in renal tissues. Sections with 4 µm width were collected on poly-L-lysine-covered slides. Primary antibodies of TNF-alpha (EMD Millipore Corporation, clone 13F9.1, Lot #Q2573230), IL-18 (Biorbyt Ltd. Cat No: orb107403) and iNOS (Cell Signaling Technology, Lot#12242) were used. Then, secondary antibody (20 min at room temperature), Streptavidin-HRP (20 min at room temperature), and DAB (3,3-diaminobenzidine tetrahydrochloride) solutions (5 min) were used in the given order. Finally, the slides were stained with hematoxylin for 10 min, and evaluation was carried out with light microscopy.

Semi-quantitative analysis was used for immunohistochemical assessments. For each section, five microscopic areas were randomly selected. The mean values of the immunohistochemical (TNF-alpha, IL-18, and iNOS) parameters were scored semi-quantitatively. Scaling was done as follows,<sup>(10)</sup>

- Grade 0: < 10% cells were stained;
- Grade I: 10%-25% cells were stained;

- Grade II: 25%-50% cells were stained;
- Grade III: > 50% cells were stained.

### Apoptosis assessment with Terminal deoxynucleotidyl transferase dUTP nick end labeling (TUNEL) method

Apoptosis causes fractures in DNA. In the TUNEL method, terminal deoxynucleotidyl transferase (TdT) adds numerous dUTP-labeled deoxynucleotides to the 3' end of a DNA strand (at 37 °C for 1 h). To detect apoptosis, in situ DNA fragmentation analysis was performed with the TUNEL (TdT-mediated dUTP nick end labeling) method. Sections with 4 µm thickness were cut from each paraffin block. After dewaxing, hydration, and serum blocking, the ApopTag Peroxidase in situ Apoptosis Detection Kit (S7100, Merck Millipore, Darmstadt, Germany) was used according to the manufacturer's protocol. After several washes, anti-digoxigenin-peroxidase was applied to the sections for 30 min at room temperature. The reaction was revealed using DAB for 6 min. After the washes, the sections were counterstained with hematoxylin for core staining. Then, the sections were examined and photographed under the light microscope, and the brown-black stained nuclei of apoptotic cells were observed. Apoptotic index (AI) was calculated in percent, using the following formula:

### Statistical analysis

The Statistical Package for the Social Sciences (SPSS, version 22, IBM, Armonk, New York 10504, NY, USA) was used for the statistical analysis. Bivariate comparisons were done with the paired samples t-test and one-way ANOVA. The statistical significance level (p) was set to <0.05.

## RESULTS

### Histopathological evaluation

When tubular necrosis data belonging to the 6<sup>th</sup> hour is evaluated, there was significant statistical increase in Control (RL) group compared to UW and HTK groups (p values are 0.010 and 0.038, respectively). When tubular necrosis data from the 12<sup>th</sup> hour is evaluated, there was a statistically



significant decrease in the RL group compared to UW and AF groups (p values are 0.035 and 0.044, respectively). There was no significant difference between the other groups.

When vacuolization data belonging to the 6<sup>th</sup> hour is evaluated, there was significant statistical increase in the RL group compared to HTK and AF groups (p values are 0.021 and 0.021, respectively). When vacuolization data from the 12<sup>th</sup> hour is evaluated, there was statistically significant increase in the RL group compared to HTK and AF groups (p values are 0.013, and 0.005, respectively). There was no significant difference between the other groups.

When dilatation in Bowman’s space data from

the 6<sup>th</sup> hour is evaluated, there was statistically significant increase in the RL group compared to HTK, UW, and AF groups (p values are 0.009, 0.009 and 0.000, respectively). When dilatation in Bowman’s space data belonging to the 12<sup>th</sup> hour is evaluated, there was statistically significant increase in the RL group compared to UW and AF groups (p values are 0.008 and 0.000, respectively). There was a statistically significant increase in the HTK group compared to the AF group (p=0.012). There was no significant difference between the other groups.

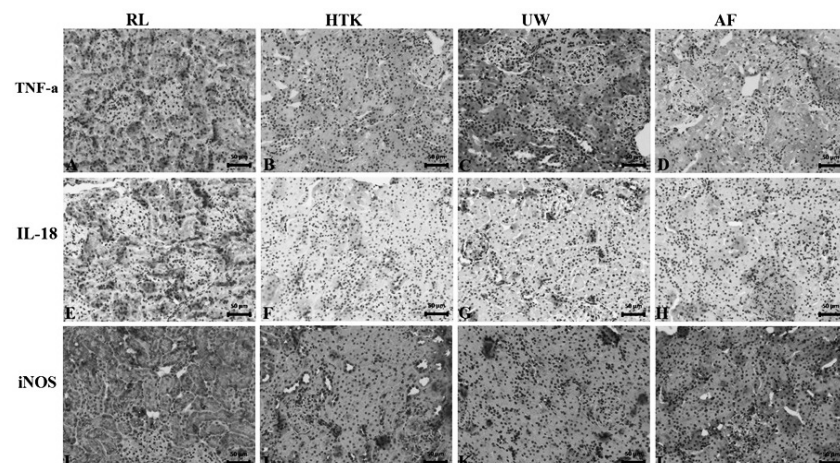
Histopathology changes and micrographs from the experimental groups can be seen in **Table 1** and **Figure 1**.

**Table 1:** Semi-quantitative assessment of histopathological findings in rat kidney tissue

6h	Tubular necrosis	Vacuolization	Dilatation of Bowman’s space	Σ Score
Group 1	1	1	1	3
Group 2	0	1	0	1
Group 3	1	1	0	2
Group 4	1	1	0	1
12h				
Group 1	2	2	1	4
Group 2	1	1	1	3
Group 3	1	1	0	2
Group 4	1	1	0	2

none: 0;  
mild: 1;  
moderate: 2;  
severe: 3;  
more severe: 4

**Figure 1:** Histological sections of the kidney tissues, which were taken in the 12th hour of the experiment, showing RL, HTK, UW, and AF groups. Blue arrows indicate vacuolization and the black arrows point to tubular necrosis (Magnification x200)



### Immunohistochemical evaluation

When the immunohistochemical results for the 6<sup>th</sup> hour for IL-18 are evaluated, there was no significant difference between the experimental groups. When the immunohistochemical results from the 12<sup>th</sup> hour for IL-18 are evaluated, there was a significant increase in the Control group (RL) compared to UW and AF groups (p values are 0.007 and 0.031, respectively). There was no significant difference between the other groups.

When the immunohistochemical results for the 6<sup>th</sup> hour for TNF- $\alpha$  are evaluated, there was a significant increase between Control Group (RL) compared to UW and HTK groups (p values are 0.024, and 0.021, respectively). When the immunohistochemical results from the 12<sup>th</sup> hour for TNF- $\alpha$  are evaluated, there was a significant increase in the Control group (RL) compared to HTK, UW, and AF groups (p values are 0.001, 0.044, and 0.003, respectively). There was no significant difference between the other groups.

When the immunohistochemical results from the 6<sup>th</sup> hour for iNOS are evaluated, there was a significant increase in the RL group compared to the UW group (p = 0.008). When the immunohistochemical results for the 12<sup>th</sup> hour for

iNOS are evaluated, there was a significant increase in the RL group compared to UW and AF groups (p values are 0.014 and 0.003, respectively). There was no significant difference between the other groups.

Immunohistochemical results and micrographs for the experimental groups can be seen in **Figure 2** and **Graphic 1**.

### Apoptotic cell detection via TUNEL method

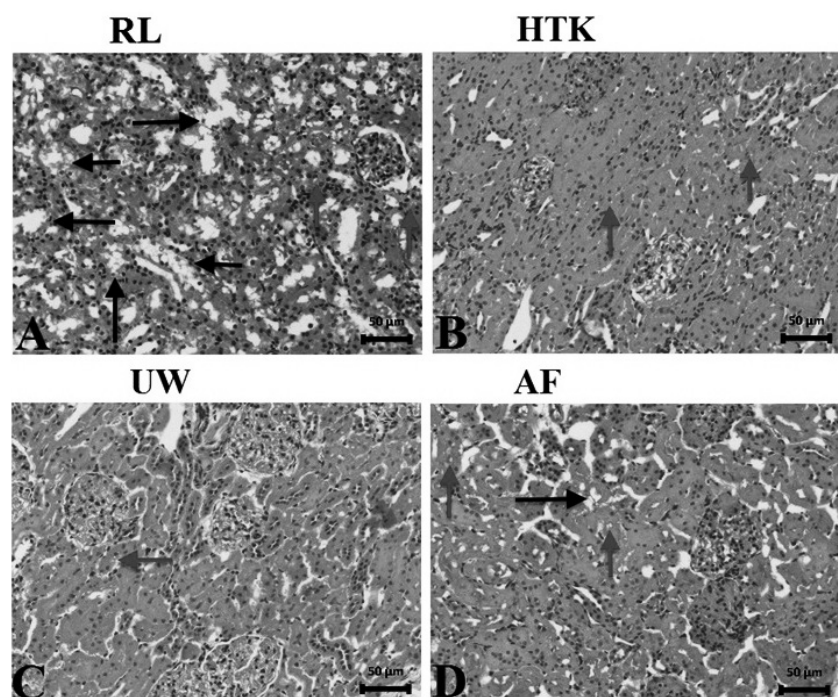
A significant increase in terms of AI results was demonstrated in the RL group compared to UW and AF groups in the 6<sup>th</sup> hour (p values are 0.002, and 0.001, respectively). There was no significant difference between the other groups.

A significant increase in terms of AI results was demonstrated in the RL group compared to HTK, UW, and AF groups in the 12<sup>th</sup> hour (p values are 0.004, 0.004, and 0.001, respectively). There was no significant difference between the other groups.

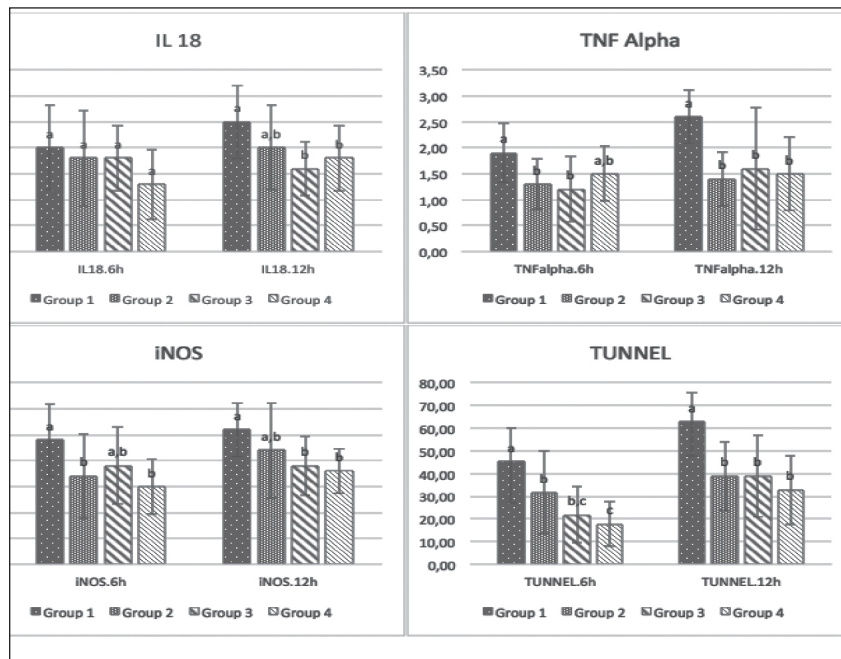
There was no statistically significant difference between the AI values of HTK, UW, and AF groups in the 6<sup>th</sup> and 12<sup>th</sup> hours.

TUNEL staining micrographs of experimental groups can be seen in **Figure 3**.

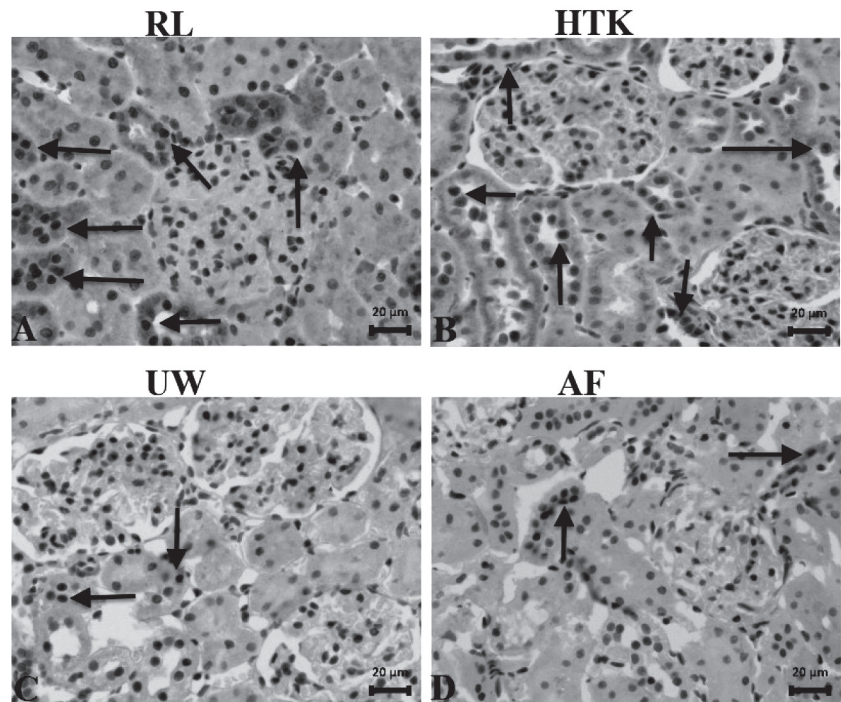
**Graphic 1.** Immunohistochemical results of all experimental groups. Letters show statistically significant differences between groups



**Figure 2:** Immunohistochemical staining of the kidney tissues for TNF-alpha, IL-18, and iNOS showing RL, HTK, UW, and AF groups in the 12<sup>th</sup> hour of the experiment (Magnification x200)



**Figure 3.** Immunohistochemical staining of kidney tissues by TUNEL showing RL, HTK, UW, and AF groups. Black arrows point to apoptotic cells (Magnification x400)



**DISCUSSION**

This study demonstrated that AF provides kidney protection similar to UW and HTK, which are standard organ preservation solutions used in kidney transplantation, at the immunohistochemical and microscopic level. Histopathologically, parameters evaluated in the

AF group presented decreased injury compared to the control group, and similar results compared to UW and HTK groups, showing that AF can be an alternative preservation solution for kidneys. In addition, a significant decrease in the number of apoptotic cells in the AF group showed the positive effect of AF on organ viability.



Immunohistochemical data also supported these results.

Cold storage of kidney grafts for transplantation includes four main components. In the order of occurrence, these are hypothermia, ischemia, hypoxia, and reperfusion. Kidneys harvested from the donor are subject to prolonged ischemia. To prevent possible injury, various organ preservation solutions were developed and improved to maintain the viability of kidneys.<sup>(11)</sup> Simple cold storage is the most prevalent and effective technique for kidney preservation. Protective effects of different organ preservation solutions have been widely studied.<sup>(4,12)</sup> The UW solution has high-viscosity and osmotically active substances. Additionally, it contains high-potassium and low-sodium, and is the gold standard solution for the preservation of liver, kidney, and pancreas.<sup>(13-14)</sup> An alternative organ preservation solution to UW is the Histidine-Tryptophan-Ketoglutarate (HTK) solution, which is cheaper and has low-viscosity compared to UW. As with UW, HTK is also being used increasingly for intra-abdominal organ preservation including kidney, pancreas, and liver. It provides rapid cooling and has fewer complications than the UW solution.<sup>(13,15)</sup>

Ringer's Lactate was one of the most preferred organ preservation solutions in early transplantation practices, but it was abandoned afterwards due to several disadvantages. It also has a capacity for rapid cooling of organs and thereby leads to a decrease in metabolism. However, after using RL solution, cellular metabolism and oxygen demand still remains around 50%.<sup>(16-17)</sup> In our study, RL was used for kidney perfusion of the control group.

Studies have shown that UW is the gold standard organ preservation solution, with its alternative being the HTK solution. Most of the literature has focused on the preserving effect of these solutions for abdominal organs and pointed out that the UW solution provides better preservation for renal grafts. It was mentioned that UW and HTK are equivalent for renal preservation.<sup>(14)</sup> Other studies suggested that no significant differences exist between HTK and

UW concerning the preservation of kidneys.<sup>(13,15,18)</sup> However, HTK is preferred more because of its low-viscosity and lower costs.<sup>(10)</sup> In our study, these two solutions proved to be similar; there was no statistical difference between UW and HTK solutions. In addition, AF was found to be as effective as UW and HTK for preservation of kidneys during the cold ischemic storage period. AI level is the parameter considered for organ viability, and it was found to be lower than the RL group. Comparing the AI values of the groups, the lowest apoptosis values in the AF group indicate that AF increases organ viability and provides effective protection. Decreased apoptotic cell counts which were obtained in the AF group can be evidence for valuable protection properties of AF, and it is predicted that postransplant success rates for kidney transplantation with AF perfusion may be high.

Recently, various potential chemical solutions have been studied for organ preservation all over the world to get better results. Schreinemachers *et al.*<sup>(19)</sup> used Polysol as an alternative organ preservation solution in their study. Also, N-acetylcysteine, L-arginine, alpha-ketoglutarate, nitroglycerin, vasosol, hyperbranched polyglycerol and prostaglandin E-1 were used for organ preservation and were shown to be promising compared to the known solutions such as UW, HTK, Celsior and Collins.<sup>(20-21)</sup>

High viscosity and high potassium concentrations may be possible reasons for abnormal delivery of organ preservation solutions into the renal segments. It is known that HTK has a lower viscosity than UW and the vasoconstriction process may be induced by high potassium concentrations. Studies reported that the preservation solutions, including high-sodium/low-potassium, were considered to be effective in stopping vasoconstriction and were better for renal preservation than low sodium-high potassium ones.<sup>(22-23)</sup>

AF has normal sodium and normal-to-low potassium concentrations similar to serum, which is promising as an alternative preserving solution for renal grafts. However, the protective effects



of AF on the renal cold ischemic injury were not studied before. It was reported that AF can be used for the cryopreservation of cell culture media.<sup>(24)</sup> Also, AF was compared with the Roswell Park Memorial Institute media and saline for skin graft preservation.<sup>(8,29)</sup> AF was used as preservation solution for the liver previously, and it was demonstrated that AF decreased apoptotic cell counts after 12 hours cold storage period.<sup>(8)</sup> Histopathological, injury grades of AF group, such as hydropic degeneration and sinusoidal dilatation, were lower than in the RL group.<sup>(8)</sup> In this study, we demonstrated the protective effect of AF on cold storage of kidneys, and the results showed that using AF as preservation solution for kidney transplantation can increase the organ viability. These results are compatible with the literature.

TNF- $\alpha$  is a proinflammatory cytokine secreted by various cells in the inflammation process.<sup>(26)</sup> IL-18 is another proinflammatory cytokine, and it was shown to be involved in renal inflammation. IL-18 is known to increase tubular necrosis and other ischemic damage parameters, especially in renal ischemia-reperfusion injury.<sup>(27)</sup> Increased IL-18 is an important parameter for evaluating renal viability.<sup>(27-29)</sup> In our study, TNF- $\alpha$  and IL-18 were evaluated immunohistochemically and there was a decrease in UW, HTK and AF groups compared to the RL group. This decrease was also statistically significant. Results for the AF group were similar to the UW and HTK groups, and there was no statistically significant difference between groups. This suggests that AF reduces proinflammatory cytokine secretion as effectively as UW and HTK for renal preservation.

iNOS is expressed in many cells, such as Kupffer cells, hepatocytes and vascular smooth muscle cells.<sup>(30)</sup> It is a marker that is frequently used in the determination of tissue injury levels, since its release increases especially during the SCS process.<sup>(10)</sup> In our study, iNOS values were significantly lower in UW, HTK and AF groups compared to the RL group, suggesting that AF provides kidney protection similar to standard preservation solutions.

As a limitation of this study, biochemical, molecular and immunological parameters such as catalase, lipid peroxidase, glutathione peroxidase, and endothelial nitric oxide synthase could be studied. The ultimate benefit of AF as an organ-preservation solution could be shown after transplantation to a receiver and by demonstrating its clinical performance.

In conclusion; our results show that AF has similar effects compared to the UW and HTK solutions and is superior to RL solution concerning the histopathological renal injury parameters, TNF-alpha, iNOS, IL-18, and TUNEL markers. Thus, as a natural tissue preservation solution, AF may be an inexpensive, promising, and readily available alternative for organ preservation.

**Acknowledgements:** The authors thank to Dr. Fatma Beyazit for collection amniotic fluid.

**Conflict of interest:** Authors declare no conflict of interest.

## BIBLIOGRAPHY

- 1) McAnulty JF, Reid TW, Waller KR, Murphy CJ. Successful six-day kidney preservation using trophic factor supplemented media and simple cold storage. *Am J Transplant.* 2002;2(8):712-8.
- 2) Mahendran AO, Barlow AD. Kidney transplantation. *Surgery (Oxford).* 2014;32(7):364-70.
- 3) Wang S, Gumper K, Tan T, Luo X, Guo H, Ming C, *et al.* A novel organ preservation solution with efficient clearance of red blood cells improves kidney transplantation in a canine model. *Cell Biosci.* 2018;8(1):28.
- 4) Marcén R, Burgos FJ, Ocaña J, Pascual J, Perez-Sanz P, Galeano C, *et al.* Wisconsin and Celsior solutions in renal preservation: a comparative preliminary study. *Transplant Proc.* 2005;37(3):1419-20.
- 5) Büyük B, Karakoç E. Effects of thiopental in cold ischemia in liver transplantation: An experimental study. *J Surg Med.* 2019;3(1):143-8.
- 6) Turhan-Haktanır N, Dilek FH, Köken G, Demir Y, Yılmaz G. Evaluation of amniotic fluid as a skin graft storage media compared with RPMI and saline. *Burns.*

- 2011;37(4):652-5.
- 7) Sterne GD, Titley OG, Christie JL. A qualitative histological assessment of various storage conditions on short term preservation of human split skin grafts. *Br J Plast Surg*. 2000;53(4):331-6.
  - 8) Büyük B, Demirci T, Adalı Y, Eroğlu HA. A new organ preservation solution for static cold storage of the liver. Amniotic fluid. *Acta Cir Bras*. 2019;34(4):e201900402.
  - 9) Estados Unidos. National Research Council. Guide for the Care and Use of Laboratory Animals [Internet]. 8<sup>th</sup> ed. Washington, DC: The National Academies Press, 2011. Disponible en: <https://www.nap.edu/catalog/12910/guide-for-the-care-and-use-of-laboratory-animals-eighth> (Consulta: 10/08/2019).
  - 10) Akbulut S, Sevmis S, Karakayali H, Bayraktar N, Unlukaplan M, Oksuz E, *et al*. Amifostine enhances the antioxidant and hepatoprotective effects of UW and HTK preservation solutions. *World J Gastroenterol*. 2014;20(34):12292-300.
  - 11) Janssen H, Janssen PH, Broelsch CE. UW is superior to Celsior and HTK in the protection of human liver endothelial cells against preservation injury. *Liver Transpl*. 2004;10(12):1514-23.
  - 12) Wang L, Wei J, Jiang S, Li HH, Fu L, Zhang J, *et al*. Effects of different storage solutions on renal ischemia tolerance after kidney transplantation in mice. *Am J Physiol Renal Physiol*. 2018;314(3):F381-7.
  - 13) Parsons RF, Guarrera J V. Preservation solutions for static cold storage of abdominal allografts: Which is best? *Curr Opin Organ Transplant*. 2014;19(2):100-7.
  - 14) Nunes P, Mota A, Figueiredo A, Macário F, Rolo F, Dias V, *et al*. Efficacy of renal preservation: comparative study of Celsior and University of Wisconsin solutions. *Transplant Proc*. 2007;39(8):2478-9.
  - 15) Agarwal A, Goggins WC, Pescovitz MD, Milgrom ML, Murdock P, Fridell JA. Comparison of histidine-tryptophan ketoglutarate and University of Wisconsin solutions as primary preservation in renal allografts undergoing pulsatile perfusion. *Transplant Proc*. 2005;37(5):2016-9.
  - 16) Caban A, Dolińska B, Budziński G, Oczkiewicz G, Ostróżka-Cieślik A, Cierpka L, *et al*. The effect of HTK solution modification by addition of thyrotropin and corticotropin on biochemical indices reflecting ischemic damage to porcine kidney. *Transplant Proc*. 2013;45(5):1720-2.
  - 17) Bessems M, Doorschodt BM, Albers PS, van Vliet AK, van Gulik TM. Wash-out of the non-heart-beating donor liver: a comparison between ringer lactate, HTK, and polysol. *Transplant Proc*. 2005;37(1):395-8.
  - 18) Mangus RS, Fridell JA, Vianna RM, Milgrom MA, Chestovich P, Chihara RK, *et al*. Comparison of histidine-tryptophan-ketoglutarate solution and University of Wisconsin solution in extended criteria liver donors. *Liver Transpl*. 2008;14(3):365-73.
  - 19) Schreinemachers MC, Doorschodt BM, Florquin S, Tolba RH. Comparison of preservation solutions for washout of kidney grafts: an experimental study. *Transplant Proc*. 2009;41(10):4072-9.
  - 20) Li S, Constantinescu I, Guan Q, Kalathottukaren MT, Brooks DE, Nguan CY, *et al*. Advantages of replacing hydroxyethyl starch in University of Wisconsin solution with hyperbranched polyglycerol for cold kidney perfusion. *J Surg Res*. 2016;205(1):59-69.
  - 21) Singh M, Odeniyi DT, Apostolov EO, Savenka A, Fite T, Wangila GW, *et al*. Protective effect of zinc-N-acetylcysteine on the rat kidney during cold storage. *Am J Physiol Physiol Renal Physiol*. 2013;305(7):1022-30.
  - 22) Moen J, Claesson K, Pienaar H, Lindell S, Ploeg RJ, McAnulty JF, *et al*. Preservation of dog liver, kidney, and pancreas using the Belzer-UW solution with a high-sodium and low-potassium content. *Transplantation*. 1989;47(6):940-5.
  - 23) Ramella SG, Hadj-Aïssa A, Barbieux A, Steghens JP, Colpart JJ, Zech P, *et al*. Evaluation of a high sodium-low potassium cold-storage solution by the isolated perfused rat kidney technique. *Nephrol Dial Transplant*. 1995;10(6):842-6.
  - 24) Thomasen H, Pauklin M, Noelle B, Geerling G, Vetter J, Steven P, *et al*. The effect of long-term storage on the biological and histological properties of cryopreserved amniotic membrane. *Curr Eye Res*. 2011;36(3):247-55.
  - 25) Turhan-Haktanir N, Sahin Ö, Yagmurca M, Köken G, Demir Y, Cosar E. Histological assessment of skin grafts stored in amniotic fluid and saline. *J Plast Surg Hand Surg*. 2010;44(4):226-30.
  - 26) Qi QA, Yang ZY, Ma KS, Lu Q, Wang SG, Li XW, *et al*. Impact of cold ischemia on cytokines after partial liver transplantation in rats. *Gen Molec Res*. 2013;12(3):4003-8.
  - 27) Zhang H, Hile KL, Asanuma H, Vanderbrink V, Franke EI, Campbell MT, *et al*. IL-18 mediates

- proapoptotic signaling in renal tubular cells through a Fas ligand-dependent mechanism. *Am J Physiol Renal Physiol.* 2011;301(1):171-8.
- 28) Matsui F, Rhee A, Hile KL, Zhang H, Meldrum KK. IL-18 induces profibrotic renal tubular cell injury via STAT3 activation. *Am J Physiol Renal Physiol.* 2013;305(7):F1014-F1021.
- 29) Parikh CR, Jani A, Mishra J, Ma Q, Kelly C, Barasch J, et al. Urine NGAL and IL-18 are predictive biomarkers for delayed graft function following kidney transplantation. *Am J Transplant.* 2006 Jul;6(7):1639-45.
- 30) Meguro M, Katsuramaki T, Nagayama M, Kimura H, Isobe M, Kimura Y, et al. A novel inhibitor of inducible nitric oxide synthase (ONO-1714) prevents critical warm ischemia-reperfusion injury in the pig liver. *Transplantation.* 2002;73(9):1439-46.

---

Recibido: 14 de octubre de 2019

En su forma corregida: 27 de octubre de 2019

Aceptación final: 4 de noviembre de 2019

Dr. Başak Büyük

Department of Histology and Embryology, Faculty of Medicine, İzmir Democracy University, İzmir, Turquía

e-mail: drbasakbuyuk@hotmail.com